

Bone Regeneration Surgery for Vertical Augmentation using the KometaBio System

Type: Case Report

Received: November 04, 2023

Published:

Citation:

Vicente Carrasco, et al. "Bone Regeneration Surgery for Vertical Augmentation using the KometaBio System".

PriMera Scientific Surgical Research and Practice 2.6 (2023): 17-24.

Copyright:

© 2023 Vicente Carrasco, et al. This is an open-access article distributed under the Creative Commons Attribution License, which permits unrestricted use, distribution, and reproduction in any medium, provided the original work is properly cited.

Dulce Ochoa-Rosales¹, Yoshamín Abnoba Moreno-Vargas^{2*} and Vicente Carrasco³

¹*School of Dentistry, Westhill University. Domingo García Ramos No 56, Cuajimalpa, Col. Prados de la Montaña, 05610 México City, Mexico*

²*Faculty of Dentistry, National Autonomous University of Mexico, Ciudad Universitaria, Coyoacán, 04510, Mexico City, México*

³*Carrasco Vicente, Department of Implantology Institute of Dental Sciences, Mexico*

***Corresponding Author:** Vicente Carrasco, Department of Implantology Institute of Dental Sciences, México.

Abstract

Introduction: When placing dental implants, there is some difficulty when rehabilitating some patients when they have low bone density. Therefore, one treatment option is bone regeneration surgery using an autologous dentin injector. And by using said injector, the aim is to promote osteogenesis, osteoinduction and osteoconduction.

Aim: To evaluate the vertical increase in a bone defect using the KometaBio system, by Cone beam Tomography.

Method: Male patient presents with a vertical bone defect in the upper anterior sector for implant placement. The bone regeneration technique of choice was placement of an autologous dentin injector, with the KometaBio system to achieve vertical increase, which was evaluated after 6 months by means of Cone beam Tomography, to subsequently continue with assessment and implant planning.

Results: A vertical bone increase was found in the area of the dental organ 21, which was: 4.07 mm in the turbinate, 0.10 mm medially and 0.98 in the apical area.

Conclusion: The autogenous dentin injector appears to be able to promote bone formation through repeated osteoinduction and osteoconduction in vertical and horizontal bone defects, providing adequate bone density for future implant placement.

Keywords: Guided bone regeneration; Autologous dentin graft; Osseointegration

Introduction

Throughout their lives, human beings are affected by tooth loss, which is not always related to old age, but is associated with different factors. Whatever the age at which this tooth loss occurs, the maxilla and mandible suffer physiological reduction of the alveolar processes until they reach a certain level, where we speak of alveolar atrophy or bone defect, causing the loss of quality and quantity of bone volume (1, 2, 3, 4, 5).

In order to rehabilitate an area with alveolar atrophy, bone regeneration surgery is imperative in order to obtain the ideal volume of bone, for the placement of implants in a prosthetically guided position, and thus achieve long-term stability, function and good aesthetic results (8), which can be carried out with different types of bone graft biomaterials. It is classified according to its nature and origin: Autograft, Allograft, Xenograft and Alloplastic.

Mineralized human dentin is used as a bone graft, being considered a “Gold Standard” biomaterial due to its great capacity to promote osteoinduction, osseconduction, osteogenesis (4), so its use as a bone regeneration biomaterial allows to obtain advantages such as increasing bone density and quality where there is some alveolar atrophy or bone defect, as well as, It avoids the risk of disease transmission and immune rejection.

In 1993, Kim and collaborators began research to develop a new graft biomaterial using human teeth; it was not until 2008, when the Tooth Bank reported in Korea the development of a material similar to autogenous bone from extracted teeth prepared as powder that was grafted to the donor patient. which promoted bone regeneration and overcame the limitations of autogenous, xenogenic and synthetic bone, which they named AutoBT (9.13, 19).

Several studies have reported that teeth extracted from patients undergoing a process of cleaning, polishing, grinding, and sterilization can be a very effective graft for filling bone defects due to the similarity in chemical composition between human dentin and bone (13). Its organic composition is 95% type I collagen and non-collagen proteins, which highlights growth factor and bone morphogenetic proteins (BMPs), which are molecules that induce bone formation, its inorganic component contains 4 types of calcium phosphates (hydroxyapatite, tricalcium phosphate, octacalcium phosphate and amorphous calcium phosphate) that They give the tooth osteoconductive properties, making it a biocompatible material (13, 19).

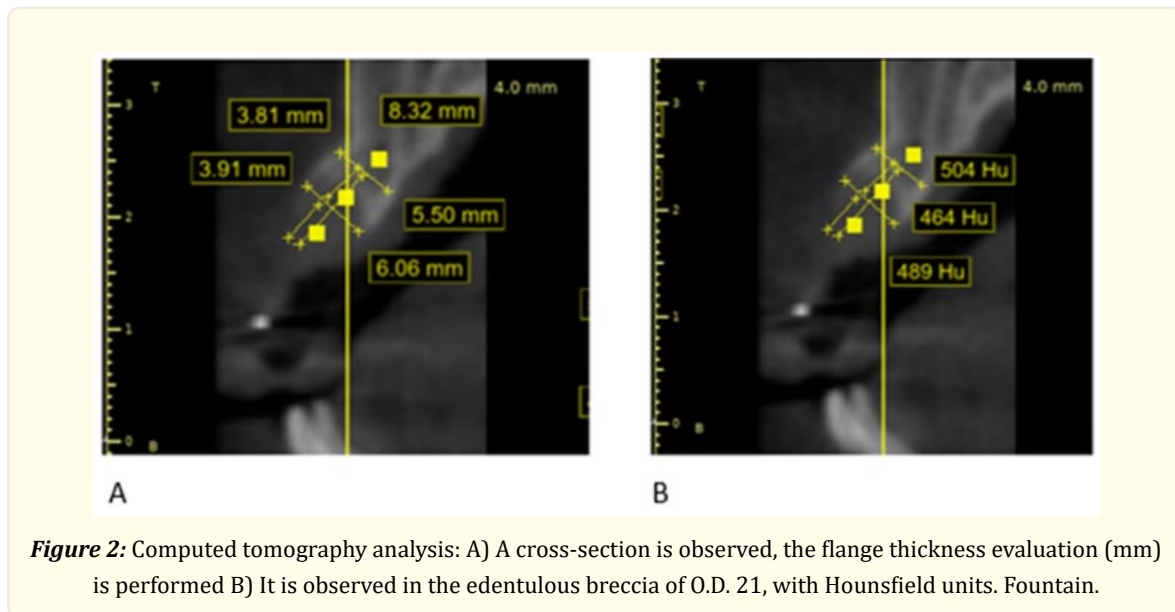
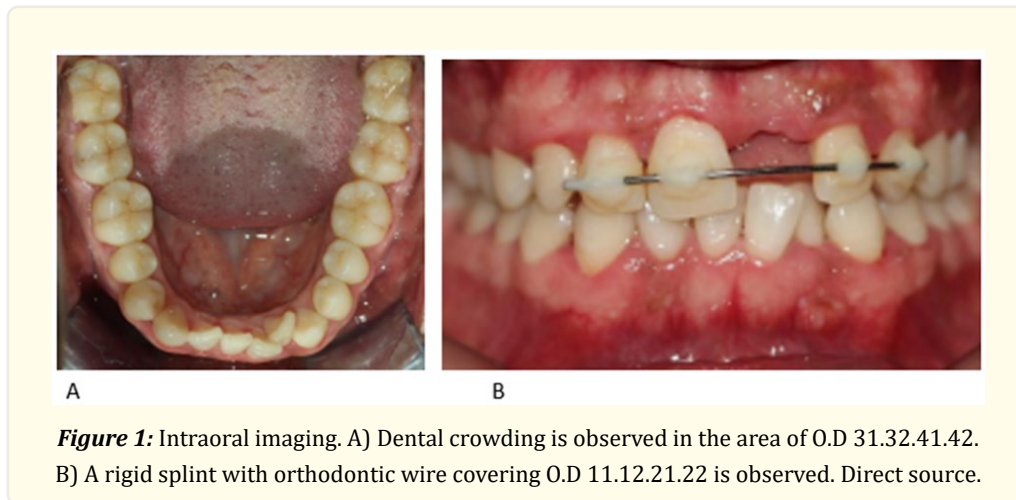
The aim of this article is to evaluate vertical growth using autologous dentin grafting in a bone defect in the maxillary area, evaluated by means of cone beam tomography, in a patient who presented at the School of Dentistry of Westhill University, where bone regeneration surgery was performed in a maxillary bone defect with autologous dentin grafting.

Presentation of the clinical case

A 38-year-old male patient presented with a rigid splint (Figure 1B), reporting that she was placed by a general dentist due to trauma in the area of the central plants, having avulsion of O.D. 21, four months earlier.

On oral examination, it was diagnosed as: superior partial edentulous (Kennedy’s Class VI), thick gingival biotype according to Kan (28), grade II mobility in the O.D. 11 (29), pathological root resorption (27) with unfavorable prognosis. In the edentulous breccia of O.D. 21, there is a bone defect in the alveolar ridge Class I Seibert (26). An orthodontic diagnosis was also given, which resulted in Skeletal Class I (30), Class III Angle, with moderate anteroinferior crowding (Figure 1A).

In the initial tomography (T0), by means of a cross-section, the length of the alveolus was measured, which was 8.32 mm. Subsequently, the division into 3 segments was performed: crestal segment (segment 1), where no measurement of alveolar thickness was obtained due to the absence of bone tissue, due to maxillary collapse; segment 2, alveolar thickness was 6.06 mm; segment 3, the thickness of the vestibulo-palatal alveolar ridge was 5.50 mm, as shown in Figure 2 A. It should be noted that reference points were taken at the crestal to medial level and were 3.91 mm (for segment 2) and 3.81 mm from medial to apical (for segment 3), to facilitate reproducibility in both T0 and T1 images.



Computed tomography (CT) showed a collapse in the height and thickness of the alveolar ridge and classified it as D4 bone according to the Hounsfield units in the perilesional area, according to the bone density according to Misch (20).

Surgical

The surgery was performed under local anesthesia (2% lidocaine). To do this, it was started with anterior middle upper alveolar nerve block and nasopalatine nerve block. Once the block was performed, the syndesmotomy was performed, along with the times of the extraction such as dislocation, pressure, traction, of the O.D. 11. A supracrestal incision was made, with a total flap displaced to the coronal with posterior vestibular discharge (Figure 3B).

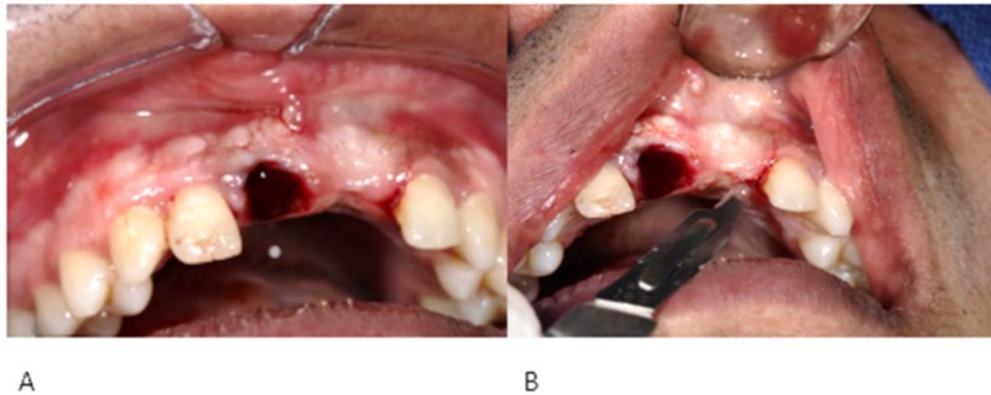


Figure 3: Surgical incision. A) The post-extraction alveolus of O.D 11 is observed and B) Subcrestal incision made with scalpel blade #15 is observed.

To perform the monocortical perforations also called “bone screening”, a #4 carbide drill was used to improve graft adhesion and nutrition, the graft.

To obtain the graft, O.D. 11 was used, which did not have a favorable prognosis to remain in the mouth, so the remains of the periodontal ligament were eliminated after extraction (Figure 4C), using a high-speed carbide cutter for a piece. Subsequently, to finish with the treatment of the tooth, prior to grinding, it was cleaned with serum and dried to be placed inside the sterile chamber of the Smart Dentin Grinder (Figure 4A), and to be crushed for 3 seconds and then sifted the particulate, using vibratory movements for 10 seconds.

From the grinding of the tooth, particles of the size of 300 to 1200 microns were obtained (Figure 4B) and stored inside the first compartment of the sterile chamber, and the particles smaller than 300 microns were stored in the second compartment, which, because they were so small, were not considered as graft material.

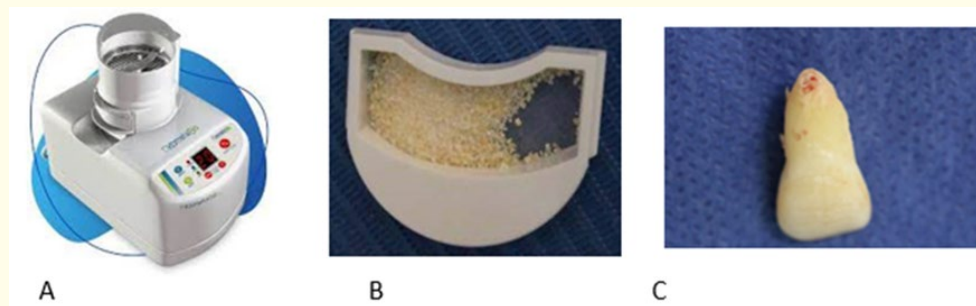


Figure 4: Graft elaboration process. A) Sterile chamber of the Smart Dentin Grinder; B) Compartment with graft particles (13). C) Dental organ cleaned of periodontal ligament debris. Direct source.

The dentin particles from the first compartment were collected and placed in a sterile container to be immersed in the Dentin Cleanser (0.5 M NaOH and 20% ethanol) for 5 minutes; it allows to dissolve all organic residues, such as bacteria and toxins from the dentin particles. After dissolving the organic residue of the graft particles with the chemical cleaner, the excess was removed with sterile gauze. The particles were then immersed in saline solution with sterile phosphate PBS (*Sterile Phosphate Buffered Saline*) for three minutes. After this time, the excess was removed, leaving them ready to be placed as grafts. The total processing time was 8 minutes.

Dentin particles were placed within the alveolus of O.D. 11 and the edentulous breccia of O.D. 21. Subsequently, it was covered with a TIRDENT® biocollagen membrane (Figure 5A and 5B) and the mucosubperiosteal flap was stabilized with horizontal mattress stitches through the opening of the alveolus (Figure 5C), using polyglycolic acid suture (Vicryl 4-0®).

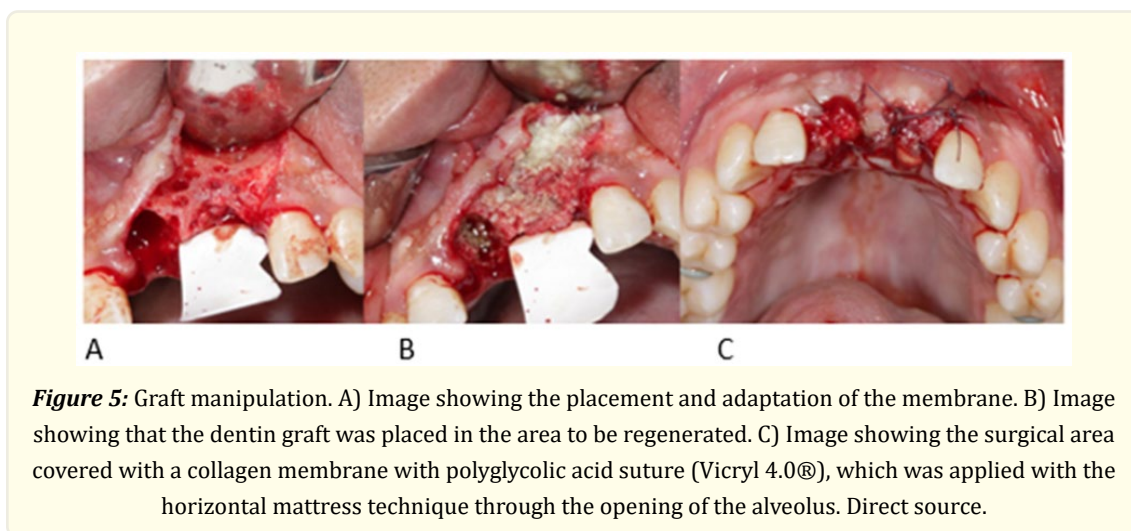


Figure 5: Graft manipulation. A) Image showing the placement and adaptation of the membrane. B) Image showing that the dentin graft was placed in the area to be regenerated. C) Image showing the surgical area covered with a collagen membrane with polyglycolic acid suture (Vicryl 4.0®), which was applied with the horizontal mattress technique through the opening of the alveolus. Direct source.

Postsurgical

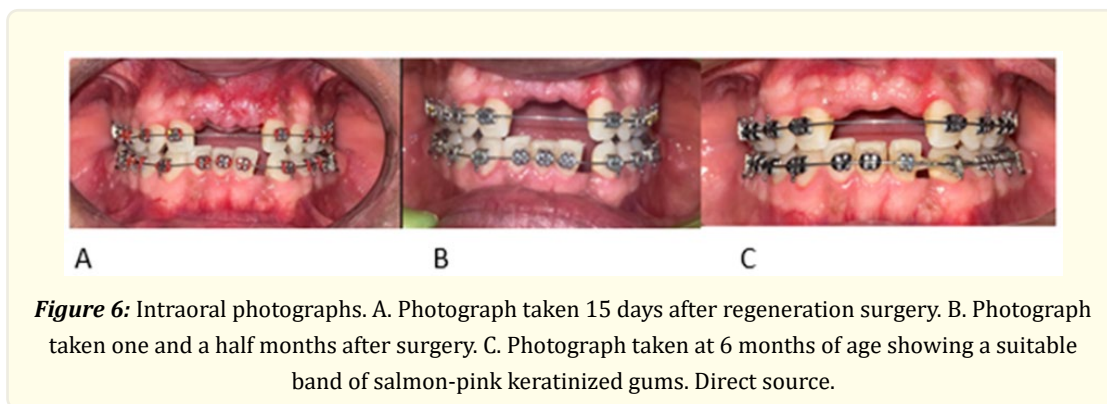
As a prophylactic measure, he was medicated with amoxicillin in 500 mg capsules, prior to surgery and, after surgery, for seven days, every 8 hours, together with analgesic and anti-inflammatory (Ibuprofen 400 mg capsules, every 8 hours for 5 days); It was also recommended to make mouthwashes with 0.2% chlorhexidine in mouthwash presentation, every 12 hours for five days.

Results

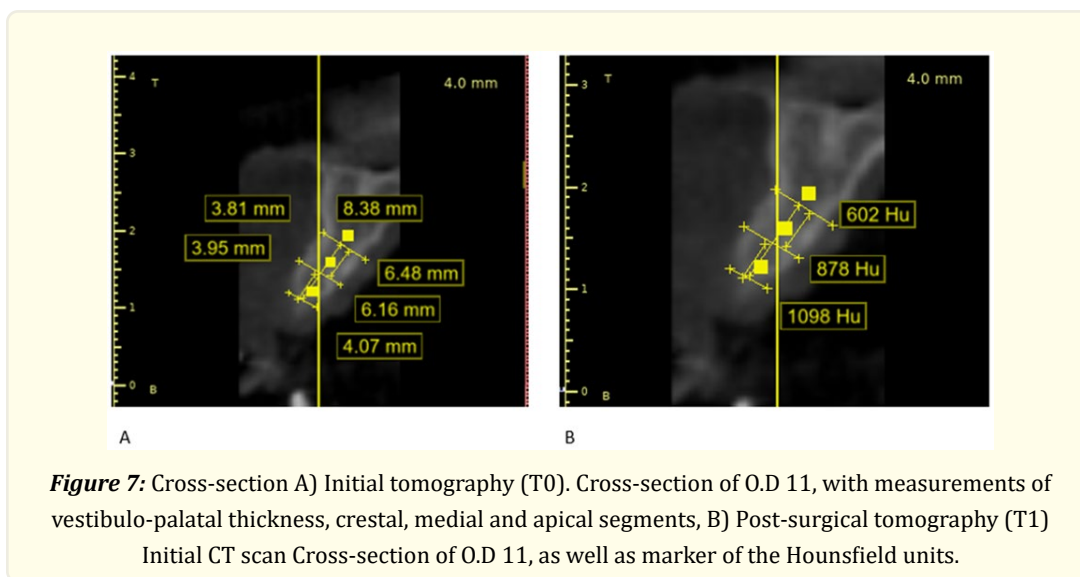
The results obtained were as follows:

15 days postoperatively, the patient was scheduled to review the healing process of the treated area for bone regeneration, and the stitches were removed. What was observed at this time was that the tissues were in an adequate healing phase, since the tissue was observed with a soft, edematous, reddish texture, giving normal signs of inflammation according to the time of evolution as shown in Figure 6A.

To follow up the patient again, the patient was scheduled a month and a half after surgery for a clinical review (Figure 6B), where it was observed that the periodontal tissues were found to be without signs of inflammation.



Six months after bone regeneration surgery with autologous dentin graft, the patient was asked to perform a cone beam tomography to compare the results obtained with the initial and postoperative tomography, where the following results were obtained: in a cross-section (Figure 7), the length of the socket was measured, which was 8.38 mm. Subsequently, it was divided into 3 segments: crestal segment (segment 1), measured 4.07 mm; segment 2, the alveolar thickness was 6.16 mm; Segment 3, 6.48 mm (Figure 7A).



Similarly, an intraoral assessment was performed to clinically review the condition of the area that was regenerated (Figure 6C). And it could be observed that an adequate band of salmon pink keratinized gum was appreciated, which shows an optimal state of oral health.

The results were satisfactory, since a vertical increase in the bone defect was obtained, in the cross-sectional the increase in the crestal segment of 4.07 mm, medial 0.10 mm, apical 0.98 was observed. Thus, in turn, an increase in the density of the newly formed bone type was observed, resulting in the crestal zone 1098 UH, medial 878 UH and apical 602 UH, classifying it into type D2 and D3 bone according to Misch (20), as shown in Table 1.

Hounsfield Units	T0	T1	Increase in Hounsfield units
Crestal Zone	489 UH	1098UH	609 UH
Medial area	464 UH	878 UH	414 UH
Apical zone	504UH	602UH	98 UH

Table 1: Comparative table of Hounsfield units for initial and post-surgical tomography.

Clinically, we were able to observe that at six months a good-sized band of salmon-pink keratinized gum was visible, which shows an optimal state of oral health.

Conclusions

In the daily practice of implant rehabilitation, frequent use of bone regeneration and alveolar preservation techniques is required in order to maintain or improve bone volume, bone density, and reduce alveolar atrophy caused by bone remodeling following tooth extraction (18). To do this, several biomaterials are used to help promote bone growth.

In the study by Kim (23), who tested the use of artificially processed teeth as grafting material, verifying what Murata (9) says, where bone was generated from a mineralized tooth, concluding that the components of tooth and bone are mineralized tissues, with a similar chemical composition, such as hydroxyapatite, type 1 collagen, non-collagenous proteins, insulin-like growth factor I (IGF-I), Transforming Growth Factor Beta (TGF-B), and bone morphogenetic proteins (BMPs), which are molecules that induce bone formation (18). Based on what Kim and Murata mention, in this clinical case shown here, it was decided to use the autologous dentin graft as a graft material, to perform bone regeneration surgery in a bone defect in the class I Seibert alveolar ridge. Kim (23), in other research, mentions: that autogenous dentin grafting allows good healing and bone remodeling at three months, in addition to the resorption of the grafted material at six months, stimulating the formation of bone tissue, which can be used in various procedures, not only for socket preservation, but also, for guided bone regeneration, alveolar ridge augmentation, and maxillary sinus floor elevation.

On the other hand, Monzón (1) mentions that, when predicting the chances of success of a dental implant, it is of great importance to take into account the type of bone, bone density, horizontal and vertical height. Therefore, based on the above, today the use of grafts has become an essential element in bone regeneration, being a complement to implantology, which has promoted the use of various methods to achieve bone growth. Based on the above, for the realization of this clinical case, the autologous dentin graft was chosen, considered as a Gold Standard graft material because it is autologous, and comes from another tooth of the same patient, having the ideal properties of biomaterial, such as osteoinduction, osseointegration and osteogenesis. An increase in volume, height and bone density was obtained, since the increase in the crestal segment of 4.07 mm, medial 0.10 mm, apical 0.98 was observed. As well as in the coronal section, there was an increase of 1.15 mm in segment 1, 1.45 mm in segment 2 and 1.58 mm in segment 3. At the same time, an increase in the density of the newly formed bone type was observed, resulting in an increase in the crestal zone 609 UH, medial 414 UH and apical 98 UH.

Acknowledgement

In particular, I would like to thank my teachers who, thanks to their unparalleled support and advice in this clinical case, were able to perform the surgical procedure with a multidisciplinary vision, to the periodontist specialist Alfredo Rafael Donís Hernández, to the prosthodontic specialists Rodrigo Hernández Girón and Miguel Ángel Pérez Perez.

References

1. Monzón T, et al. "Bone grafts in oral implantology". Rev Méd.2014;36(4).
2. García M., et al. "Use of autologous bone grafts and biomaterials in patients with alveolar atrophy". Matanzas. Rev.Med.2019;41(6): 1424-1437.
3. Fischer T, et al. "Grafting of biological materials: synthetic bone grafts versus xenografts in maxillary sinus elevation". Quintessence.(2018;6(1)).
Primer Scientific Surgical Research and Practice <https://primerascientific.com/pssrp>
4. Bustamante CD., et al. "Tibial bone grafting in oral and maxillofacial surgery: indications and description of the technique, purpose of three cases". Int. J. Odontostomat.2021;15(1): 286-292.
5. Sanzana-L., et al. "Clinical and histological evidence of soft tissue regeneration from a porcine collagenous matrix. Case Report". Int. j interdiscip. Dent. 2022;15(1): 79-83.

6. García C, Cabrera C and Santa P. "Autogenous dentin graft applied for residual rim preservation. Bravo Clinical Case Report". Mexican Dental Journal.2019;23(3): 182-191.
7. Díaz HI., et al. "Onlay bone grafting. Presentation of a case". Medicevic. 2015;21(4).
8. Martínez A., et al. "Bone grafts and biomaterials in oral implantology. Bone grafts and bone substitutes in implant dentistry". Advances In Odontostomatology 2018; 34(3).
9. Estrade DM. How to Transform Extracted Teeth into An Autologous Bone Graft in a Single Dental Appointment, The Surgical Tribune, French edition 2015.
10. Soung-K., et al. "In-Woong Um Autogenous teeth used for bone grafting: a comparison with traditional grafting materials". Oral Surg Oral Med Oral Pathol Oral Radiol.2014;117: e39-e45.
11. Avila-OG., et al. "Effect of alveolar ridge preservation after tooth extraction: a systematic review and meta-analysis". Journal of Dental Research. 2014;93(10): 950-958.
12. Joseph YK Kana., et al. Evaluation of gingival biotype in the aesthetic zone: visual inspection vs. direct measurement 14.3 (2010): 236-243.
13. Botero JE and Bedoya E. "Determinants of Periodontal Diagnosis". Rev. Clin. Implantol periodontics. Rehabil. Oral 2010;3(2) 94-99.
14. Afonso P., et al. "External root resorption: a case report". AMC.2015;19(2): 381-388.
15. García M, García S, Bascones Martínez A. "Techniques for alveolar preservation and alveolar ridge augmentation: A review of the literature". Av Periodon Implantol 2016; 28(2): 71-81.
16. Ugalde M. Classification of malocclusion in the anteroposterior, vertical and transverse planes.2007;3: 97-109.
17. Romero M, Veloso C, Krupp S. "Evaluation of bone quality at dental implant sites with computed tomography". Acta odontologica Venezolan.2016;54(2) .
18. Sánchez L. et al. "Use of autogenous dentin as graft material in oral surgery". Cient Dent.2019;16(2):155-160.