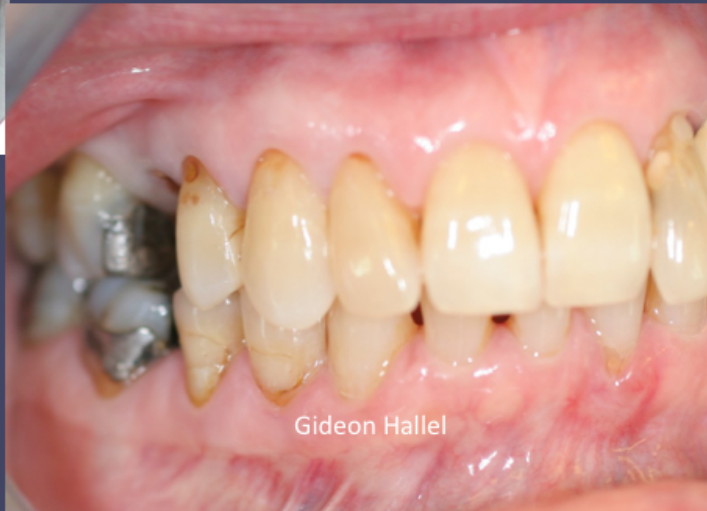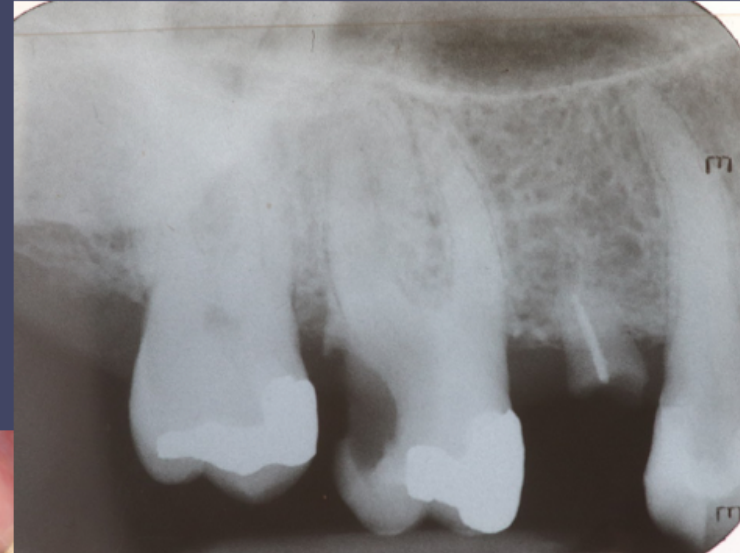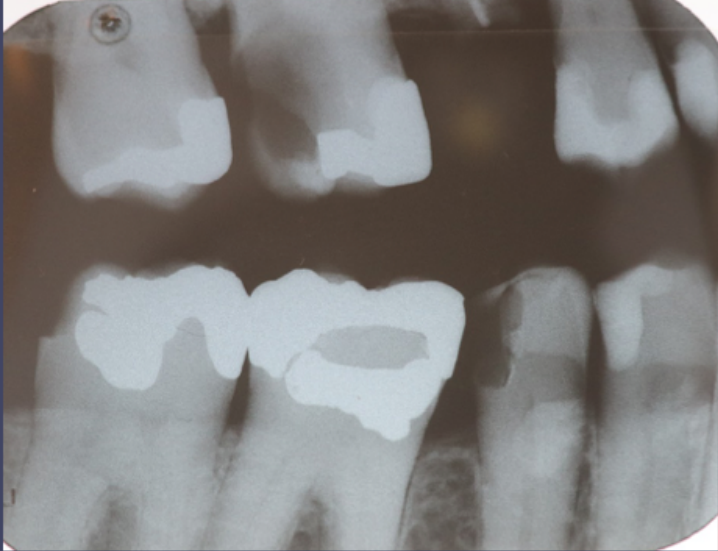


Implant in a grinded
dentin preserved
molar socket
5.5 years follow up

Gideon Hallel DMD MPA

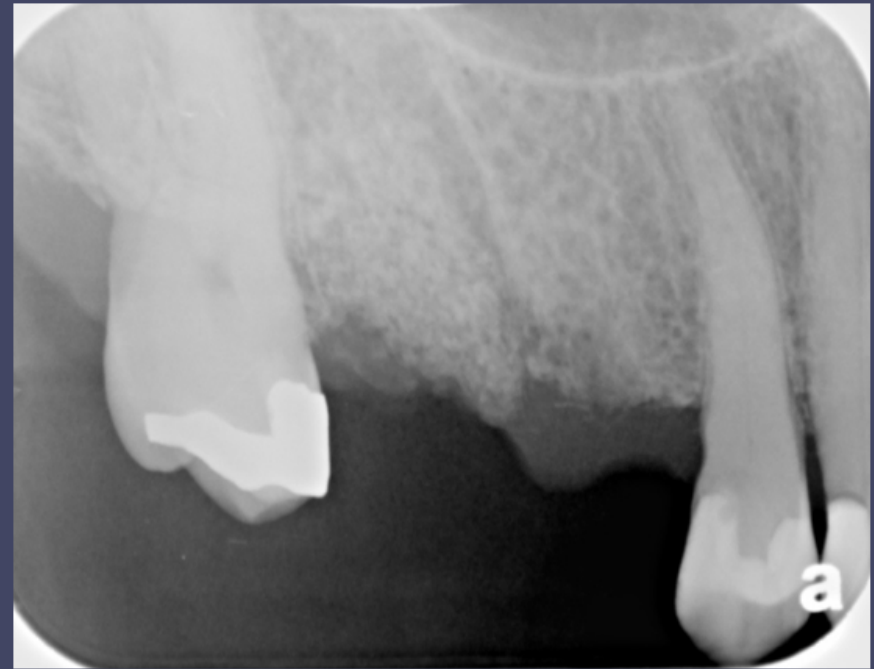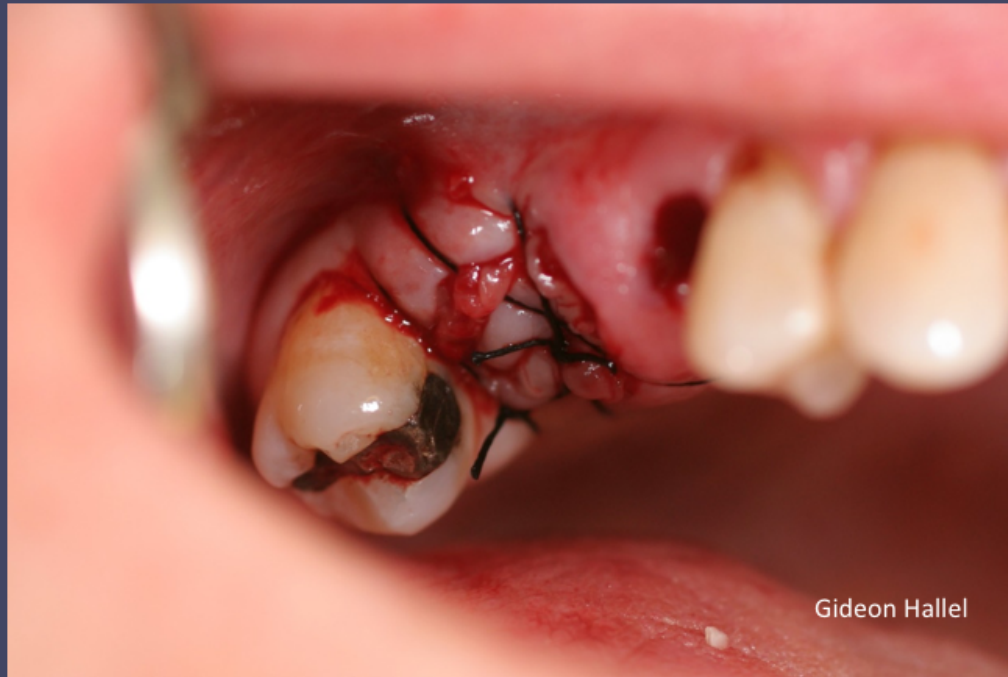info@drhallel.com

Pre – op 2013

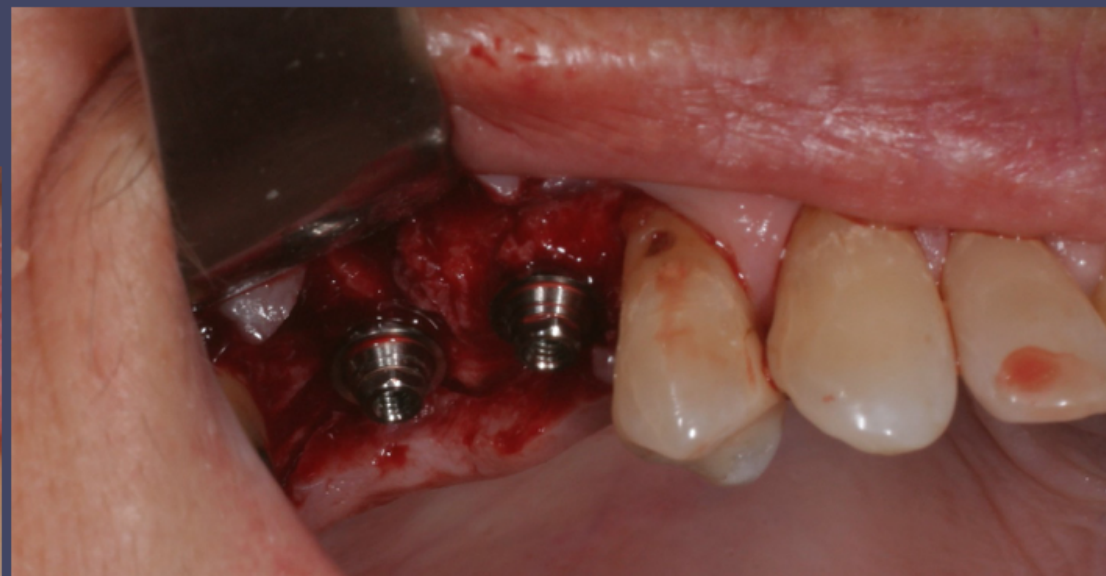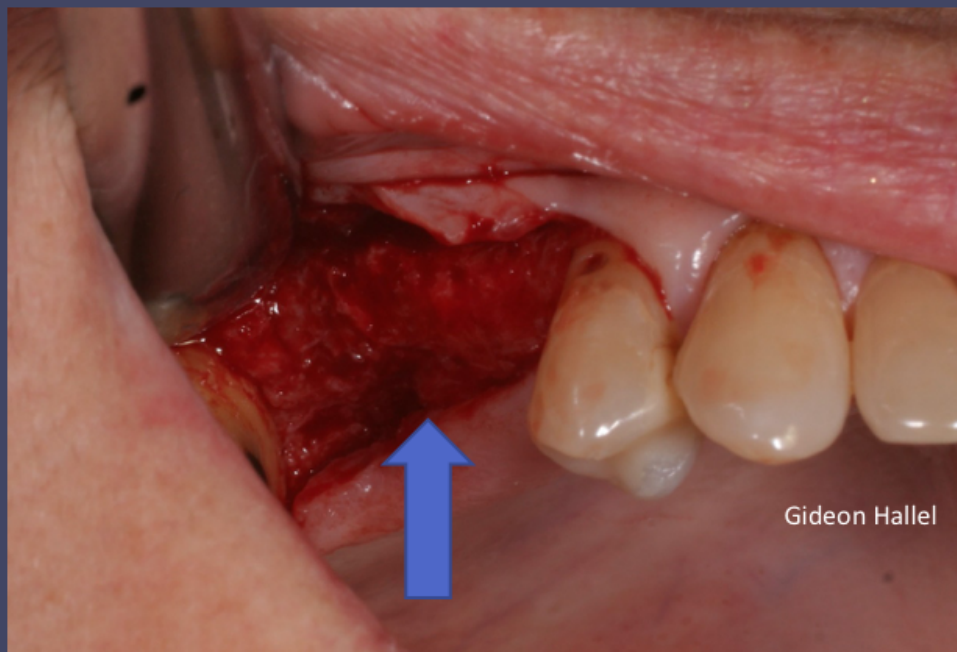


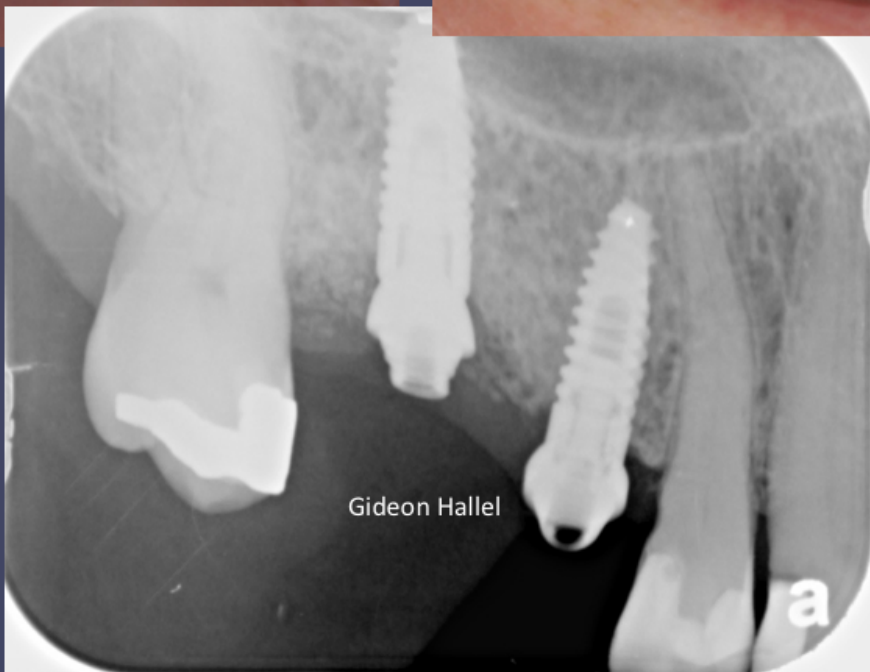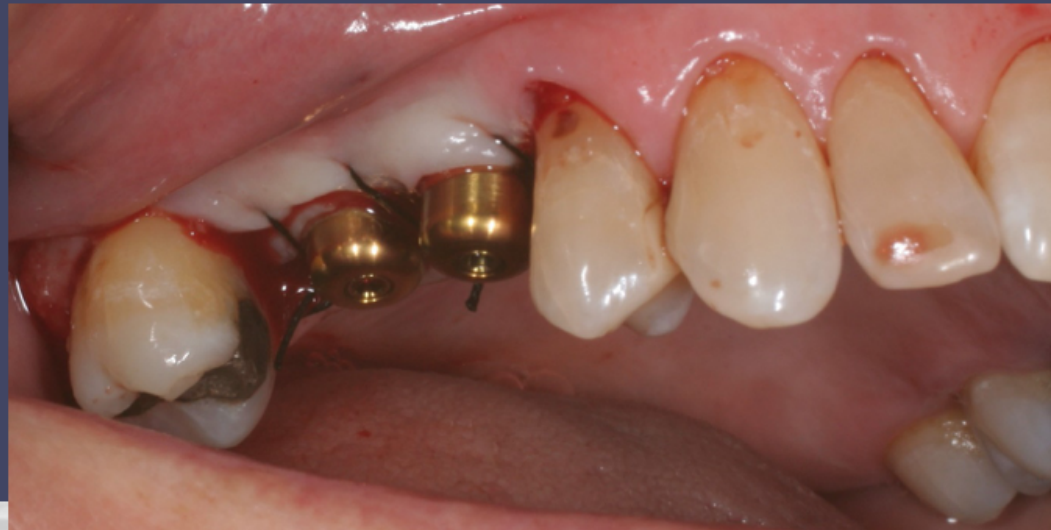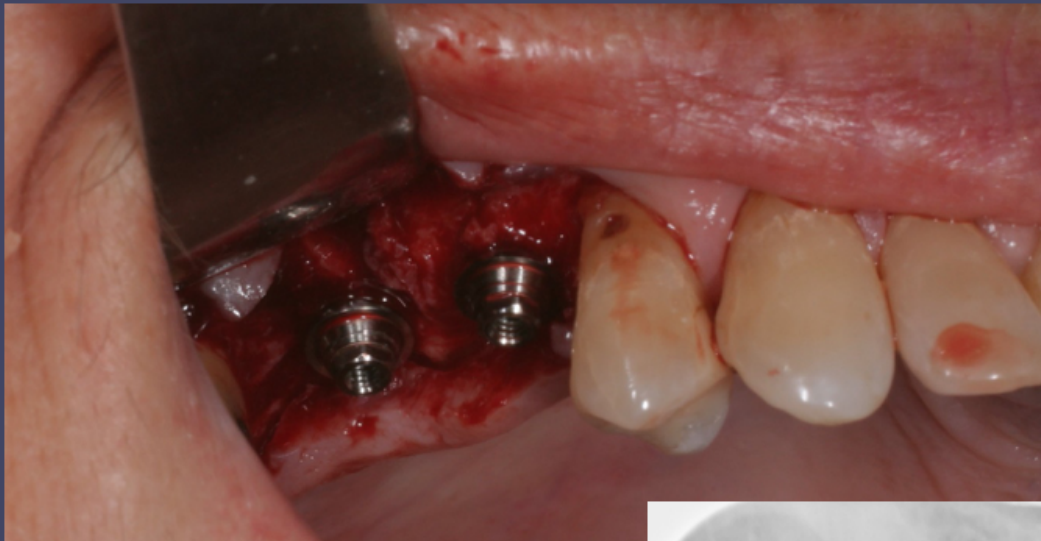Gideon Hallel

Socket preservation with dentin jan 2014 (no membrane) .

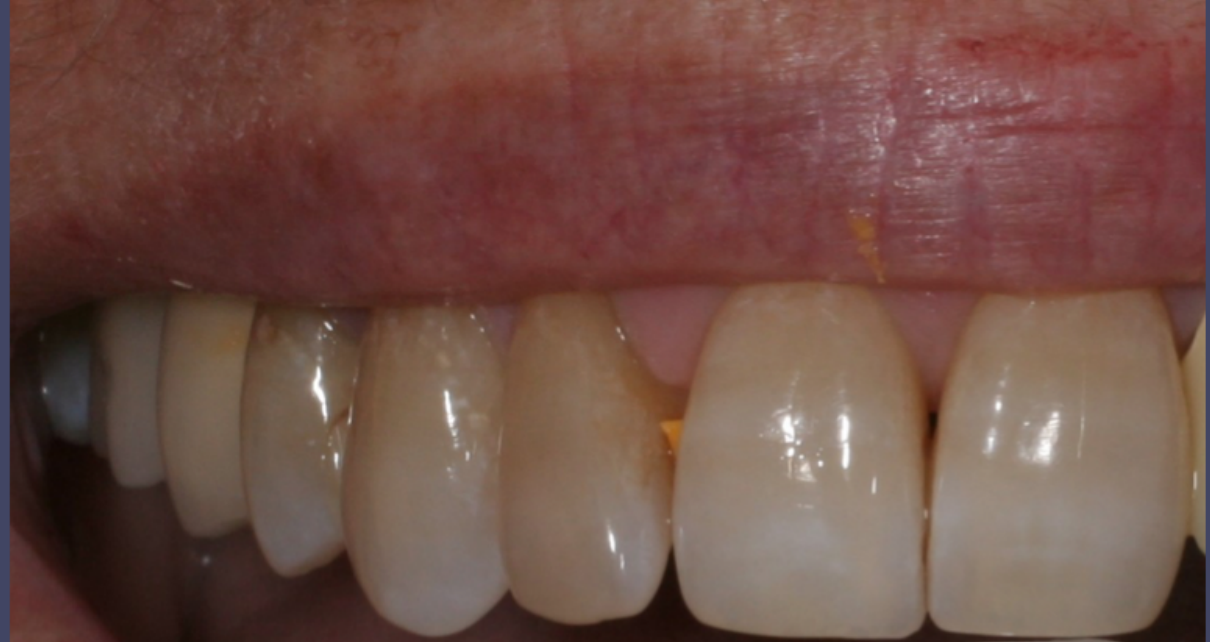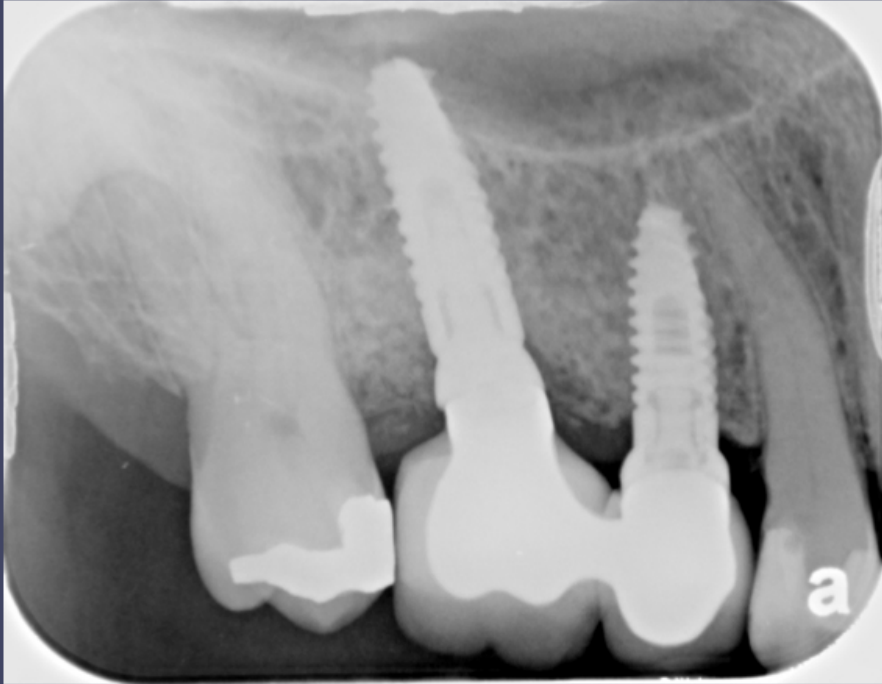


implants insertion after 3 months, note
dentin particles mar. 2014

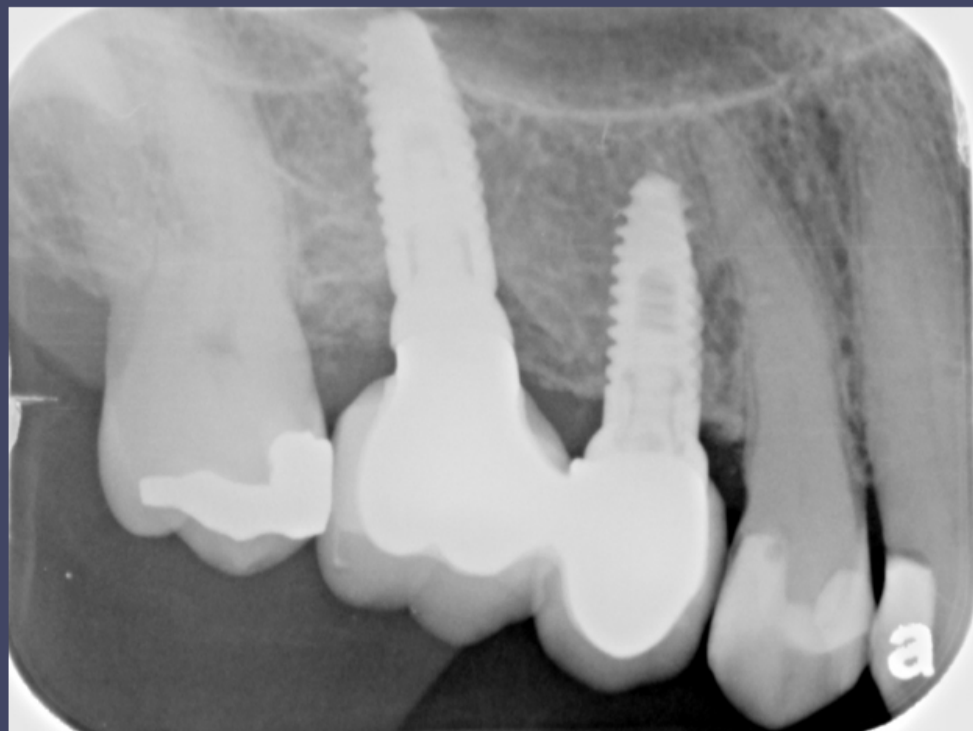




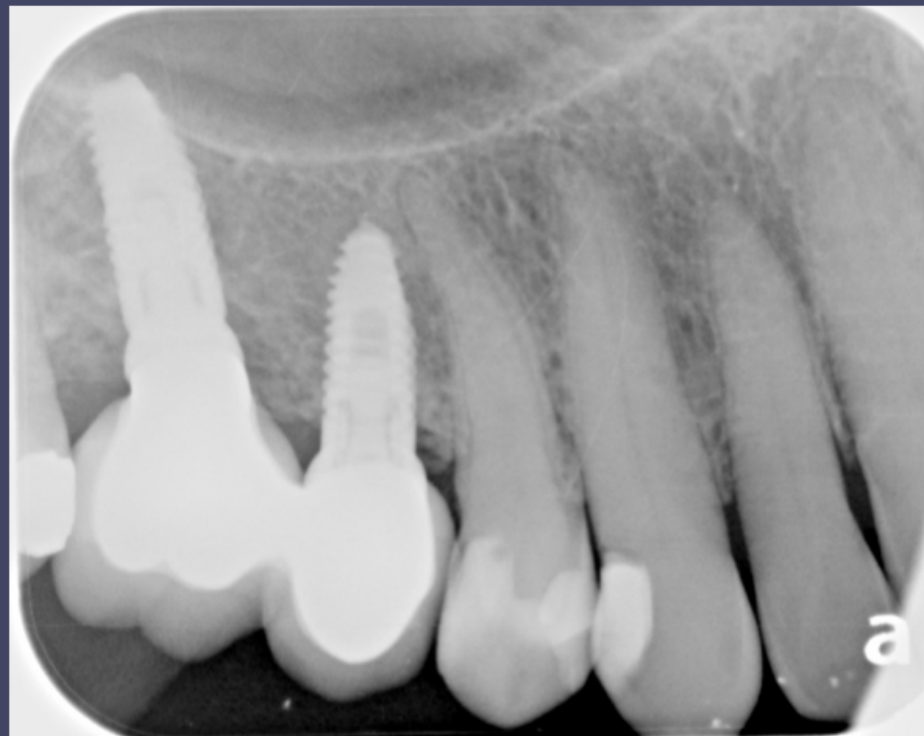
Final crowns on multi units jul. 2014



Aug 2015

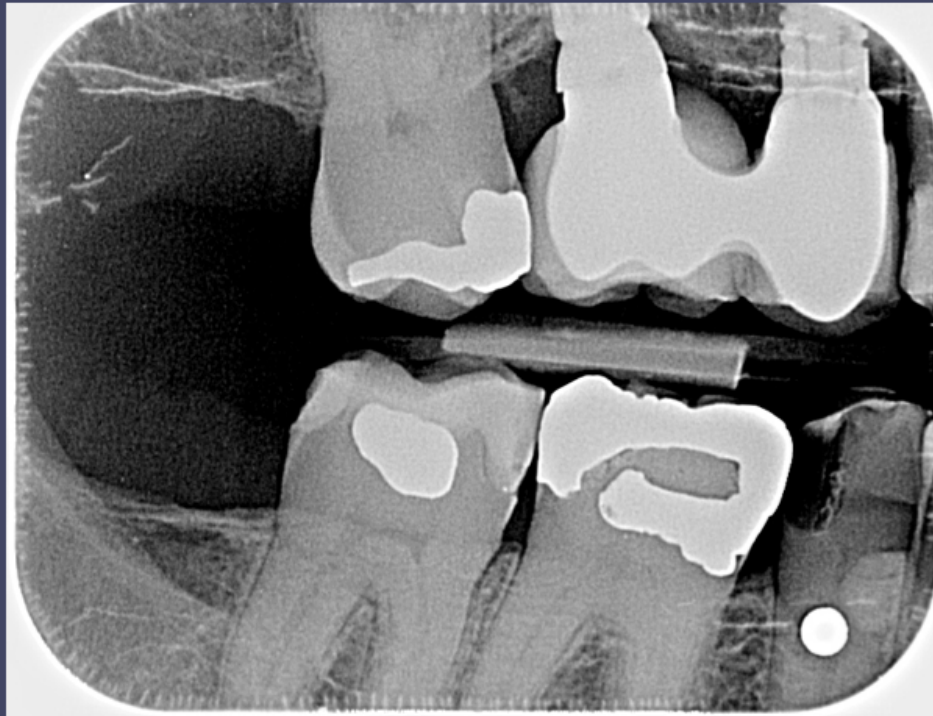


Jun 2017

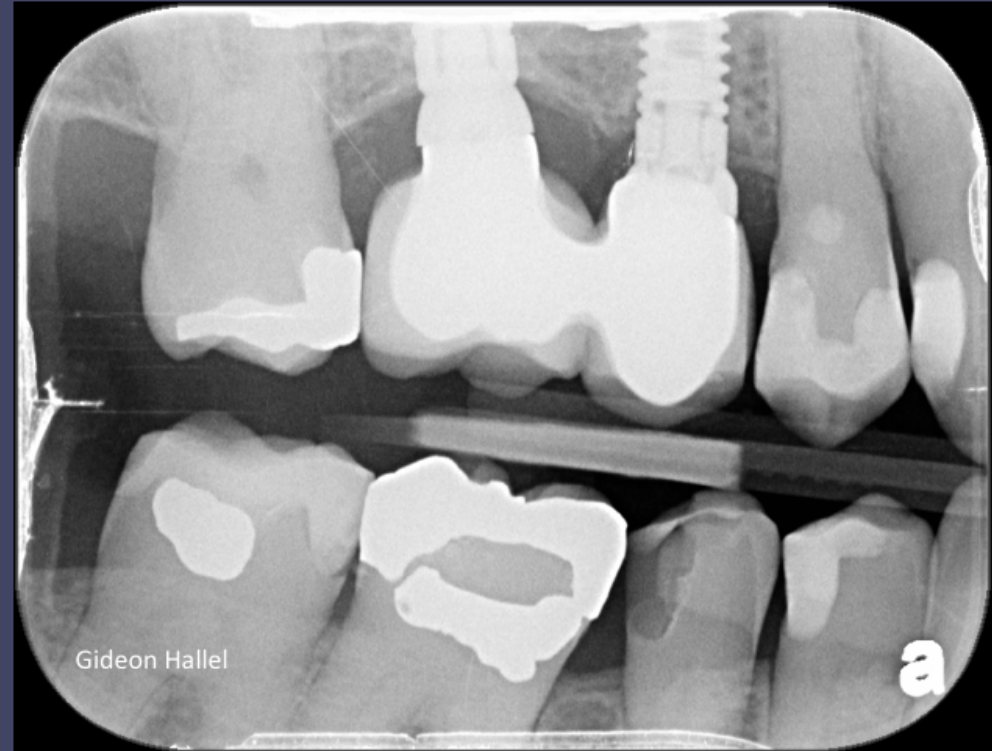

Bite wing comparison

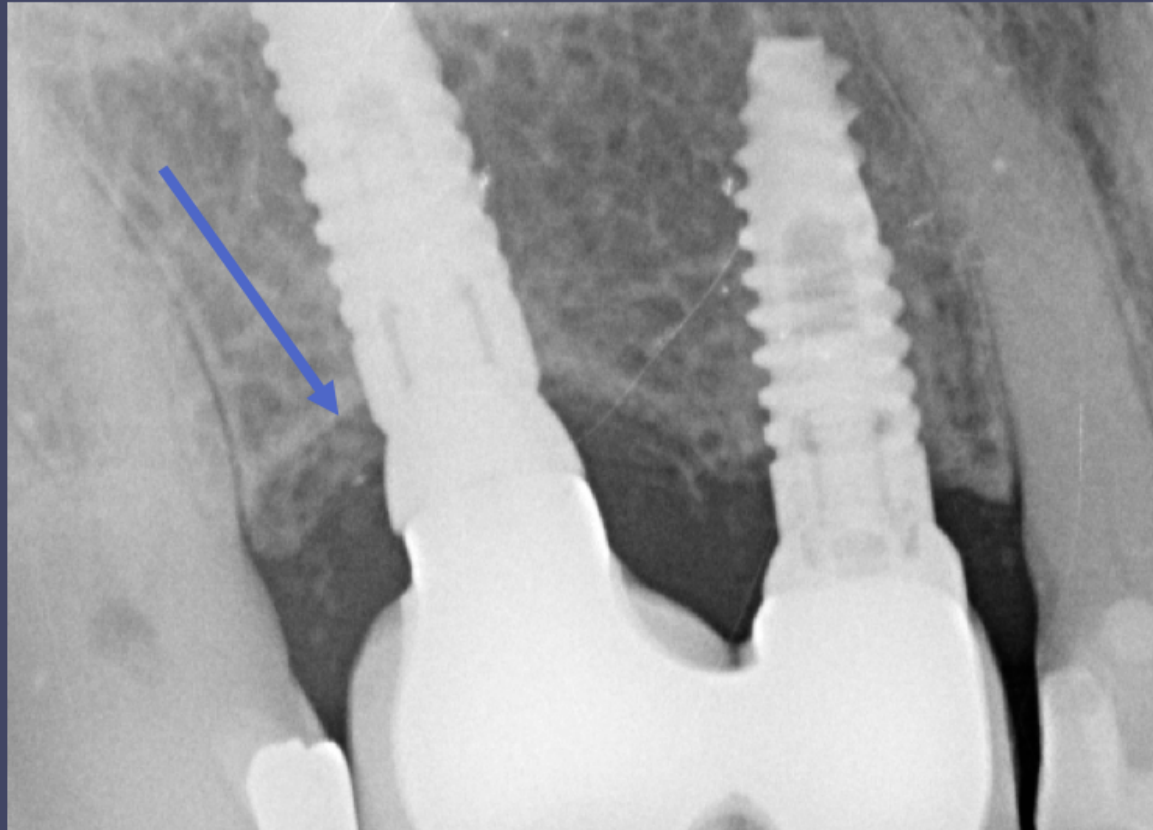
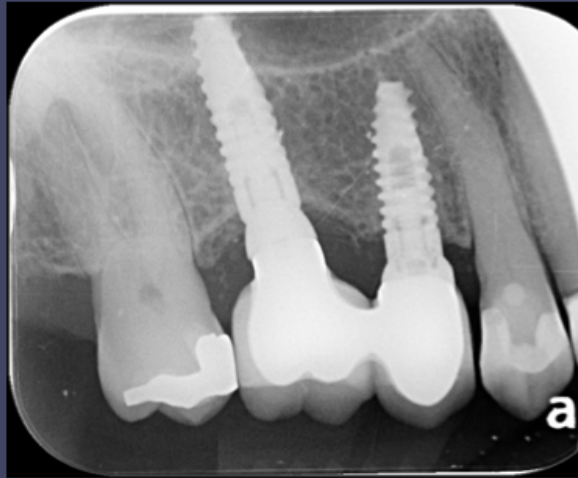
Jun 2017



Sep 2019



Sep 2019 note dentin maturation



Dentin maturation 2014 – 2019

