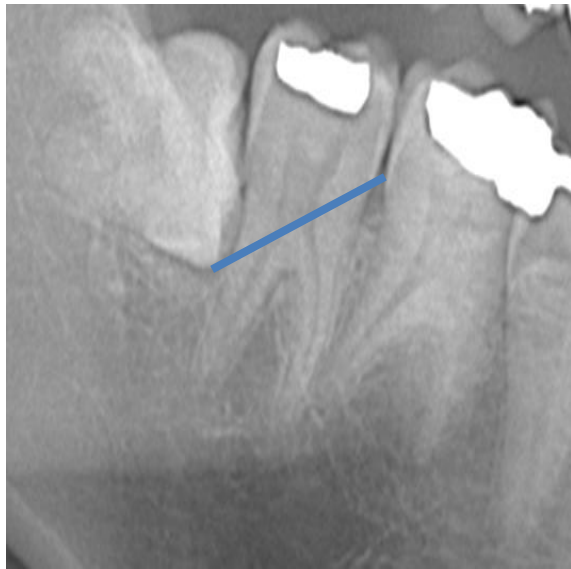

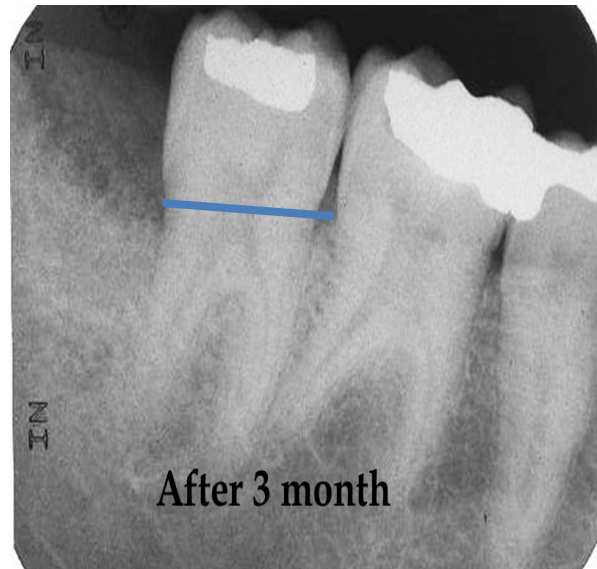Bone management: Two comparative cases

The following two cases present bone management using autologous dentin graft. These two cases show how effective dentin graft is to build up bone mass rapidly as well as maintain bone level over time. In these specific cases the graft is used in order to support the distal root.

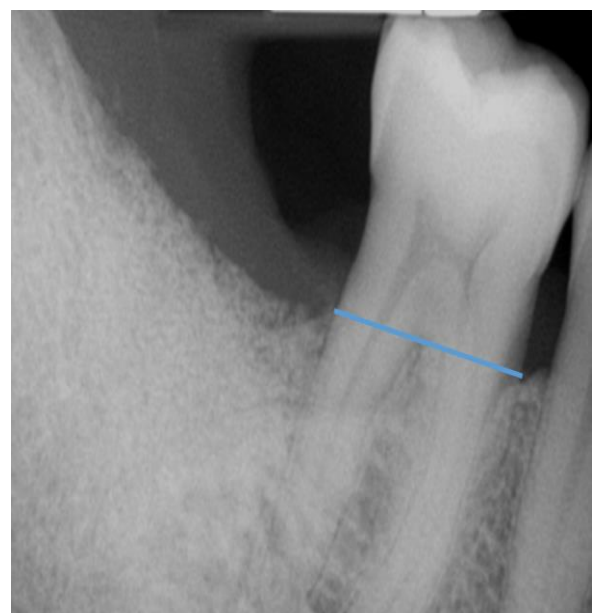
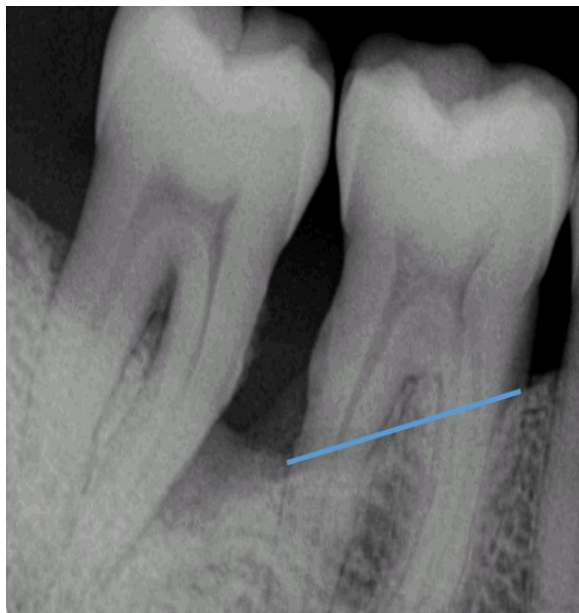Before



After



Case A: Before and after grafting. 0 weeks and 3 months follow up. Prof. Casp Nardy.



Case B: Before and after grafting. 0 weeks and 1 month follow up. Dr. Cifuni.